

Indications: Anteromedial Osteoarthritis

Total knee arthroplasty is an effective treatment for most types of arthritis of the knee and requires little of the joint's anatomy to be intact for a successful outcome. On the other hand, unicompartmental arthroplasty can only succeed if the rest of the knee is functionally intact before surgery. We will discuss, first, the pathology of osteoarthritis (OA) of the knee and then how to ascertain, before operating, that the ligaments are all functionally normal and the retained articular surfaces capable of resuming their weight-bearing role.

History

The components of the OUKA prosthesis were first used (from 1976 to 1984) as a bi-compartmental knee replacement (Fig. 4.1). The patients had severe OA or rheumatoid arthritis and since, at that time, there were no proven alternative treatments, there were no specific indications. The first step towards defining a role for the implant was taken when the results of these operations were reviewed and it was found that the anatomical state of the anterior cruciate ligament (ACL) at the time of surgery was an important determinant of the long-term outcome¹. In 1992, we reported a six-fold difference in the 7-year cumulative survival of the prosthesis between knees with or without a functioning ACL at the time of surgery, irrespective of the primary disease and of all the other variables measured². This was the first publication to offer statistical evidence of the importance of that ligament in the kinematics of unconstrained resurfacing implants. During the same period we had, incidentally, observed that in osteoarthritic knees with an intact ACL, articular surface damage was usually limited to the medial compartment, with the rest of the

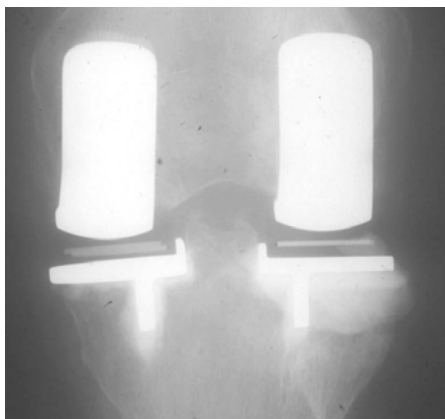


Figure 4.1 Bicompartamental Oxford Knee replacement (Phase 1, 1976-84).

joint remaining healthy. Taken together, the two observations suggested that these cases would be appropriate for treatment with the meniscal prosthesis and, since 1982, the implant has been mainly used for medial replacement in OA knees with an intact ACL³.

Subsequently, we published a more detailed study of the pattern of cartilage damage in arthritis, correlating the preoperative clinical and radiological signs with the intraoperative findings during unicompartmental surgery⁴. In that paper we introduced the term 'anteromedial osteoarthritis' to describe the subgroup of varus knees in which both cruciate ligaments and the MCL are functionally normal, and in which the cartilage and bone erosions on the tibial plateau are in the anterior and central parts of the medial compartment with a corresponding lesion on the inferior medial femoral condyle.

We now believe that anteromedial OA is the most common indication for UKA and is present in about half the patients needing knee replacement. The condition can be recognised by a consistent association between the clinical and radiological signs and the pathological lesions that cause them.

Anteromedial osteoarthritis (Figures 4.2 & 4.3)

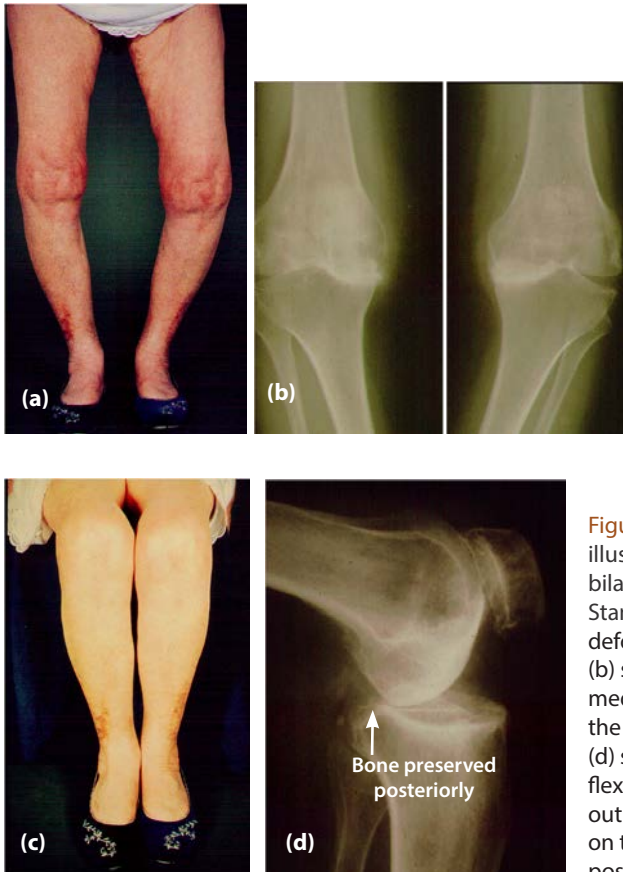


Figure 4.2 (a)–(d) The patient illustrated had unusually severe bilateral anteromedial OA. Standing, (a) she has marked varus deformities and the radiographs (b) show deep erosions of both medial tibial plateaux. Sitting, (c) the varus corrects. The radiograph (d) shows that this is because in flexion the medial condyles roll out of the anteromedial erosions on to the intact articular surfaces posteriorly.

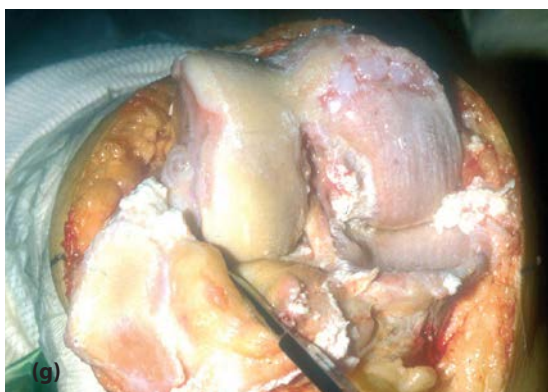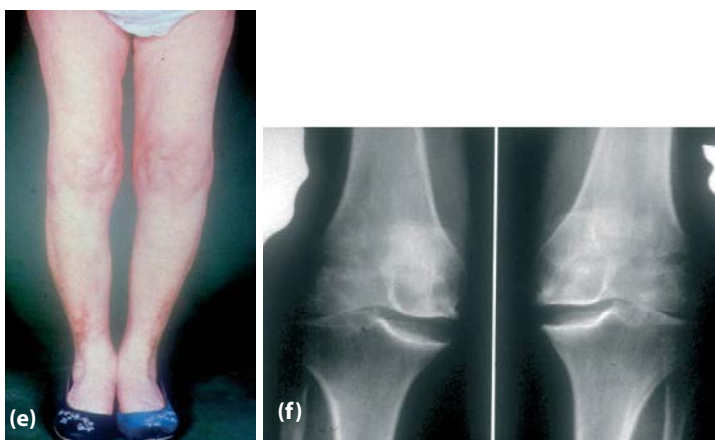

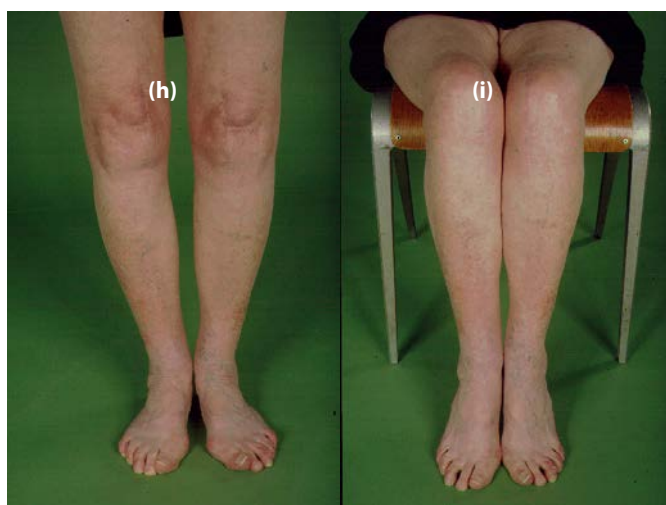
Figure 4.2 (e) –(i) Because the varus corrected every time the knees were flexed, structural shortening of the medial collateral ligament could not occur. Therefore, with the knees flexed a little, the patient could correct the varus with her own muscles (e). On the radiographs (f), the varus is corrected by applied valgus force. The intraoperative picture (g) shows the anatomical features of anteromedial OA. Note the intact ACL.



(Reproduced with permission and copyright © of the British Editorial Society of Bone and Joint Surgery [White SH, Ludkowski PF, Goodfellow JW. Anteromedial osteoarthritis of the knee. *J Bone Joint Surg [Br]* 1991; **73-B**: 582–6.]) (h) & (i) show clinical photographs of the same patient with well functioning knees 23 years after her bilateral Oxford medial knee replacements. The patient died in 2013, aged 100 years.

Principal physical signs

1. Pain in the knee is present on standing and is severe when walking. It is relieved by sitting.
2. With the knee (as near as possible) fully extended, the leg is in varus (5–15°) and the deformity cannot be corrected.
3. With the knee flexed 20° or more, the varus can be corrected.
4. With the knee flexed to 90°, the varus corrects spontaneously.

Principal anatomical features

At surgery, knees with the above mentioned physical signs regularly demonstrate the following anatomical features, some of which are visible in the intraoperative photograph shown in Figure 4.2(g) and all of which are illustrated in the diagrams in Figure 4.3.

1. Both cruciate ligaments are functionally normal, though the ACL may have suffered some damage and may have longitudinal splits.
2. The cartilage on the tibia is eroded, and eburnated bone is exposed, anteriorly and/or centrally on the medial plateau. An area of full-thickness cartilage is always preserved at the back of the plateau (Fig. 4.3(a)).
3. The cartilage on the inferior articular surface of the medial femoral condyle is eroded, and eburnated bone is exposed. The posterior surface of the condyle retains its full-thickness cartilage (Fig. 4.3(a)).
4. The weight bearing articular cartilage of the lateral compartment, although often fibrillated, preserves its full thickness (Fig. 4.3(b)). In many cases, a full thickness ulcer can be present on the medial border of the lateral femoral condyle (see Fig 5.4) ⁵.
5. The medial collateral ligament (MCL) is of normal length (Figs. 4.3(d–f)).
6. The posterior capsule is shortened (Fig. 4.3(a)).

Correlations

The observed sites of articular surface damage, together with the intact status of the cruciate ligaments and the MCL, explain the symptoms and physical signs.

1. The cruciate ligaments maintain the normal pattern of 'rollback' of the femur on the tibia in the sagittal plane (see Chapter 3) and thereby preserve the distinction between the damaged contact areas in extension (the anterior tibial plateau and the inferior surface of the medial femoral condyle) (Figs. 4.3(a) and (b)) and the intact contact areas in flexion (the posterior tibial plateau and the posterior surface of the femoral condyle) (Figs. 4.3(c) and (d)). The short posterior capsule causes the flexion deformity (Fig. 4.3(a)).
2. The varus deformity of the extended leg, (and the pain felt on standing and walking), are caused by loss of cartilage and bone from the contact areas in extension (Figs. 4.3(a) and 4.3(b)).